

Meningoencephalitis due to SARS-CoV-2 and tuberculosis co-infection: a case report from Indonesia



Retnaningsih^{1*}, Bima Purwaamijaya², Dodik Tugasworo¹, Yovita Andhitara¹, Rahmi Ardhini¹, Aditya Kurnianto¹, Nur Afany³, Jacob Bunyamin⁴, Fatiha Sri Utami¹, Ida Ayu Sogata¹, Hairuzaman¹

¹Department of Neurology, Faculty of Medicine, Universitas Diponegoro-Dr. Kariadi General Hospital, Semarang, Indonesia;

²Gatot Soebroto Army Hospital, Jakarta, Indonesia;

³Kramat Jati Hospital, Jakarta, Indonesia;

⁴National Diponegoro Hospital, Semarang, Indonesia;

*Corresponding author: Retnaningsih;

Department of Neurology, Faculty of Medicine, Universitas Diponegoro-Dr.Kariadi General Hospital, Semarang, Indonesia; retnaku_icu@yahoo.com

Received: 2021-02-02

Accepted: 2021-07-20

Published: 2021-07-31

ABSTRACT

Introduction: The novel coronavirus which firstly detected in December 2019 in Wuhan, China, has been known to cause neurological dysfunction either by directly or indirectly infecting the brain.

Case: We are reporting a case of meningoencephalitis due to co-infection of *M. tuberculosis* and SARS-CoV-2 in a hospital in Indonesia. A 26-year-old gentleman working as a courier in a Sars-Cov-2 red zone without adequate protection complained frequent headaches since a month to admission. *M. tuberculosis* was detected on very low level by GenXpert® and rapid test for SARS-CoV-2 was nonreactive. Repeated GenXpert® showed detected *M. tuberculosis* with undetected rifampicin resistance. Subsequent CSF SARS-CoV-2 PCR was positive although the oropharyngeal swab was negative.

Conclusion: The report of pulmonary co-infection of TB and SARS-COV-2 has been published, however, to our best knowledge there has been no report of neurological co-infection to date. We are reporting the report of CNS co-infection from our country.

Keywords: COVID-19, Meningoencephalitis, Tuberculosis, SARS-CoV-2.

Cite This Article: Retnaningsih., Purwaamijaya, B., Tugasworo, D., Andhitara, Y., Ardhini, R., Kurnianto, A., Afany, N., Bunyamin, J., Utami, F.S., Sogata, I.A., Hairuzaman. 2021. Meningoencephalitis due to SARS-CoV-2 and tuberculosis co-infection: a case report from Indonesia. *Bali Medical Journal* 10(2): 673-676. DOI: 10.15562/bmj.v10i2.2235

INTRODUCTION

The novel coronavirus which firstly detected in December 2019 in Wuhan, China, has been emerging as a global health emergency.¹ The virus has been known to cause neurological dysfunction either by directly infecting the brain or indirectly as a result of strong activation from systemic immunological reaction.² Human brain cells express the angiotensin-converting enzyme 2 (ACE2) protein in its surface, a protein involved in blood pressure regulation and a receptor for the virus to enter and infect the cells.³ ACE2 is also found in the endothelial cells constructing the blood vessels. Infection of the endothelial cells allows the virus to transport from the respiratory system to blood and crosses the blood-brain barrier to the brain, in which the virus replicates and subsequently causing neurological dysfunction.^{4,5} ACE2 expression is mainly found in both neuron and glial cells of the brainstem and regions responsible

for cardiovascular function regulation, ie. subfornix, paraventricular nuclei, solitary tract nuclei, and rostral ventrolateral medulla regions.^{6,7} We are reporting a case of meningoencephalitis due to co-infection of *M. tuberculosis* and SARS-CoV-2 in a hospital in Indonesia.

CASE REPORT

A 26-year-old gentleman working as a courier in a Sars-Cov-2 red zone without adequate protection complained frequent headache since a month to admission which resolves with over-the-counter drug and rest. Seven days prior to admission, he developed continuous fever, chilling, and shortness of breath, although decreased appetite and coughing were denied. Two days prior to admission his speech started to become disoriented and tended to be drowsy. Past history of tuberculosis, diabetes, hypertension, head injury, and blood transfusion were denied while alcohol consumption was moderate. He

was initially admitted in a small hospital on 16th April 2020 for being disoriented and drowsy with initial GCS E₃M₆V₄, BP 110/60 mmHg, HR 86 bpm, RR 27 pm, temperature 38°C, and oxygen saturation 98%. As his condition deteriorated (GCS E₃M₅V₄), he was then transferred to a secondary-care hospital on the same day. Initial lab results showed leukocytosis (14,970/mm³) with left shifting and increased absolute neutrophil counts (12,790) and he was admitted in the isolation ward. Chest X-ray can be seen on [figure 1](#).

In day 4, he had further decreased consciousness (GCS E₂M₄V₂), developed hypotension (BP 80/60 mmHg), and appeared dyspneic. In day 5, he developed acute respiratory failure (RR 38 pm), pre-shock (BP 70/50 mmHg), and haematemesis which required prompt intubation, fluid resuscitation, and ICU transfer. Blood tests revealed respiratory alkalosis (pH 7.47, PaCO₂ 28 mmHg, PaO₂ 67 mmHg, HCO₃ 23

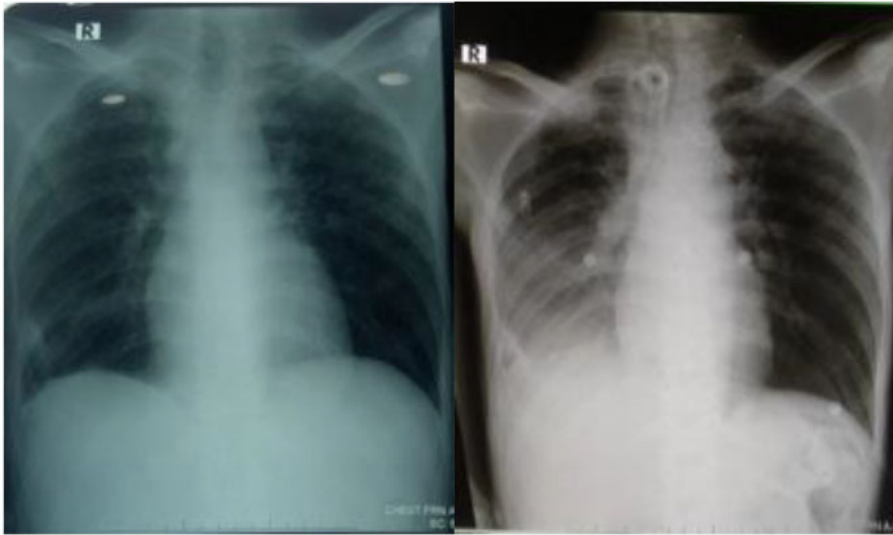


Figure 1. Chest X-Ray on first admission (Day 1) and readmission (Day 20).

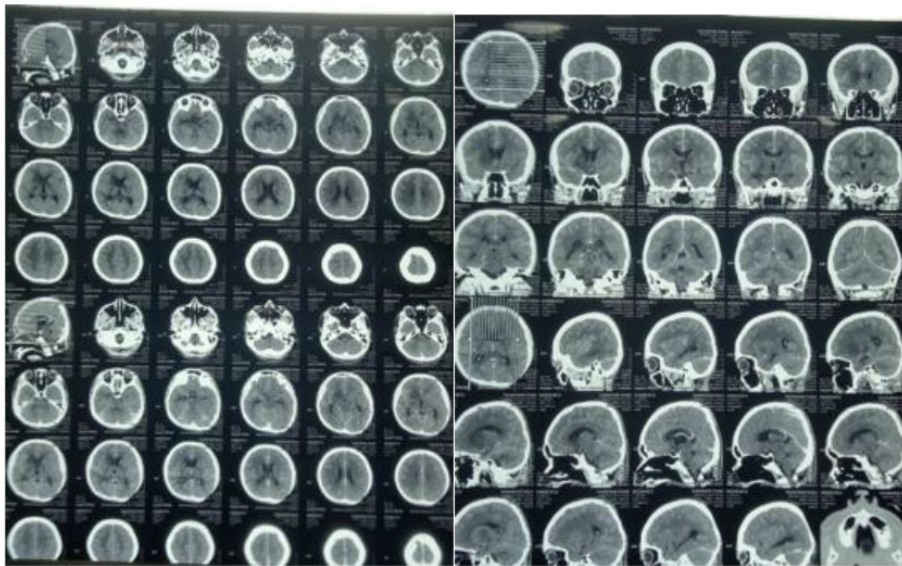


Figure 2. Contrast Head CT showing basal meningeal enhancement (Day 5).

mEq/L, BE -4), leukocytosis (23,960/mm³), hyponatremia (120 mEq/L), mild increase of serum transaminases (AST 58.3 IU/L ALT 59.4 IU/L), reactive HbsAg, and low CD4 lymphocyte count (33/mm³). *M. tuberculosis* was detected on very low level by GenXpert® and rapid test for SARS-CoV-2 was nonreactive. Lumbar puncture parameters matched tuberculosis infection [cloudy cerebrospinal fluid (CSF), leukocyte 113/μL, Polymorph nuclear cells (PMN) 13, Mononuclear (MN) cells 87, protein 100, glucose 27 (blood glucose 101 mg/dL), nonne positive, pandy negative]. Contrast head

CT showed increased enhancement in basal cistern characteristic of tuberculous meningitis, accompanied by bilateral basal ganglia ischemia and mild hydrocephalus (Figure 2). The patient was diagnosed with *M. tuberculosis* meningitis with immediate start of anti-tuberculosis treatment, acute respiratory failure, septic shock, hyponatremia, and hepatitis B.

In day 6, his condition improved (GCS E₃M₅V_{et}, BP 110/70 mmHg, SpO₂ 99%, FiO₂ 60%, V-SIMS PS 10, PEEP 5, VT 400, RR 12 pm) with dobutamine (10 mcg/kgBW/min) and norepinephrine (0.1 mcg/kgBW/min) infusions. Sputum

results were positive for acid-fast bacilli and GenXpert® MTB-RIF-Assay was indeterminate. In day 7, the blood pressure stabilized (110/70 mmHg with norepinephrine infusions), SpO₂ 99%, FiO₂ 50%, CPAP PEEP 5, PS 6, the patient was afebrile, the leukocyte (12,600/mm³) and sodium (135 mEq/L) levels were improved. Repeated GenXpert® showed detected *M. tuberculosis* with undetected rifampicin resistance. In Day 8, CSF SARS-CoV-2 PCR was positive, thus the diagnosis was tuberculous meningitis, confirmed COVID-19 encephalitis, and septic shock with improvement. In Day 9, we performed percutaneous dilated tracheostomy (PDT) and the day after the patient started 6 liters per minute oxygen (GCS E₃M₄V_{tc}, SpO₂ 99%, FiO₂ 50%, V-SIMV PS 6 PEEP 5). In day 17 (3rd May 2020), patient was discharged for home care with GCS E₃M₄V_{tc}, SpO₂ 99% with speaking valve.

Three days after discharge (6th May 2020) the patient was readmitted due to decreased consciousness, unresponsiveness, fever, and dyspnea. His GCS was E₂M₂V_{tc}, BP 130/80 mmHg, pulse 154 bpm, RR 40 pm, temperature 38°C, SpO₂ 99% with speaking valve. He was admitted to the ICU and planned for an oropharyngeal swab. Blood gas analysis revealed respiratory alkalosis, complete blood count showed leukocytosis (20,360/mm³) with left shifting, increased neutrophil-lymphocyte ratio (17.11), and increased absolute neutrophil count (18,140). Quantitative CRP was elevated (13.63), coagulation tests were normal, HCV and HIV were negative. Chest X-Ray suggested right pleural effusion and active tuberculosis (Figure 1). In day 4 readmission, the patient showed improvement in consciousness and respiratory rate and was maintained with 15 liters per minute oxygen via speaking valve (GCS E₃M₄V_{tc}, BP 110/70 mmHg, pulse 100 bpm, RR 24 pm, temperature 38°C, SpO₂ 99%). In day 8 readmission, oropharyngeal swab result was negative and the fever started to diminish. In day 11 readmission, he was discharged for the second time for home care with latest GCS E₃M₄V_{tc}.

DISCUSSION

We are reporting the co-infection of *M. tuberculosis* and SARS-CoV-2 causing meningoencephalitis in our hospital in Indonesia, with TB remains a public health problem with the incidence rate 391 per 100,000 population.⁸ Central nervous system (CNS) tuberculosis is caused by the hematogenous dissemination of the bacilli into the brain, leading to small subependymal or subpial foci called 'Rich foci' which may be ruptured and lead to the spread of *M. tuberculosis* to subarachnoid space.^{9,10} The established risk factors of tuberculous meningitis are alcoholism, diabetes, malignancy, and corticosteroid treatment, while raised intracranial pressure, acute infarction, and hyponatremia are known complications.¹¹ An optimal microbial diagnosis of *M. tuberculosis* remains challenging, with the 42.0% sensitivity of GenXpert[®] compared to 64.0% by PCR, thus relying on clinical and other supporting examinations is essential.¹²

SARS-CoV-2 has been an emerging global problem and creating public health emergencies in many countries. Recent literatures have suggested that SARS-CoV-2 infection is able to invade the nervous system via blood circulation, neuronal transmission, and immune system from the respiratory system, although the evidence is still rare for the circulatory pathway.⁸ The presence of SARS-CoV-2 in the systemic circulation causes viral spike protein interaction with ACE2 which is expressed in the capillary endothelial, leading to endothelial destruction and viral introduction to the brain.^{13,14} In the neuronal level, interaction with ACE2 progresses to viral budding accompanied with non-inflammatory neuronal damage. Another possible migration pathway for SARS-CoV-2 to the brain is believed to be through the cribriform plate adjacent to the olfactory bulb.¹⁰ The release of secondary inflammatory reaction in blood may affect the blood-brain-barrier (BBB) permeability mediated by cytokines leading to viral infiltration and the subsequent viral encephalitis.^{15,16}

The SARS-CoV was detected in the brain neurons and the cerebrospinal fluid (CSF) after seven days since the transmission from the olfactory tract leading to

inflammatory and demyelination.⁸ Neural damage caused by viral infection may be mediated by systemic immunological system, as the severe infection is related to the development of systemic inflammatory response syndrome (SIRS).¹⁷ This may be initiated abnormally in severe pneumonia due to SARS-CoV-2 infection, where early anti-inflammatory agent intervention may effectively prevent and reduced the risk of further neuronal damage.^{18,19} Moreover, both CoV and CoV-2 infection has been responsible in numerous death due to multi-organ failure induced by SIRS.^{20,21} Neurotropic viral infection like SARS-CoV may activate glial cells and induce pro-inflammatory state where the release of IL-6, an integral part of the cytokine storm which correlated positively with the severity of COVID-19 symptom.^{19,22}

Our case demonstrated the neuroinvasive potentials of SARS-CoV-2 infection, an unusual manifestation of COVID-19 similar to reports from Japan and China.^{23,24} The report regarding pulmonary co-infection of TB and SARS-COV-2 has been published. However, we failed to find the report of CNS manifestation.²⁴ Active or latent *M. Tuberculosis* infection was observed to possibly increase the susceptibility and severity of COVID-19 therefore *M. Tuberculosis* check-in SARS-CoV-2 positive patients was recommended.²⁵ We observed an initial negative immunological result of SARS-CoV-2, however the result from lumbar puncture examination was positive of N-SAR-CoV-2. This showed the high level of SARS-CoV-2 nucleic acid in the CSF in this case and that the result was dependent of the viral concentration level in biologic fluids. However, the oropharyngeal swab test was negative, similar to Moriguchi *et al.*, who detected SARS-CoV-2-RNA in CSF but not in the nasopharyngeal swab.² Our experience showed that this should not become the reason for excluding SARS-CoV-2 infection diagnosis in suspected patients.

We observed that immunocompromised patients with tuberculosis infection might also be infected with SARS-CoV-2, causing a horizontal infection. Encephalitic symptoms might be the first manifestations besides respiratory problems to screen undetected SARS-

CoV-2 patients, and the health care providers need to be aware that SARS-CoV-2 infected patients may develop encephalopathy during admission. The diagnostic measurement for SARS-CoV-2 encephalitis best provided by the RT-PCR whenever possible, especially in countries with limited resources and facilities as such countries might be severely affected by the global pandemic, as this method requires more cost, highly-trained staffs, separated facilities with high biosafety levels, and rigorous quality control. Our report emphasized the nervous system's involvement in the SARS-CoV-2 and highlighted the importance of diagnostic approach in SARS-CoV-2 related encephalitis in the developing country.

CONCLUSION

Co-infection between *M. tuberculosis* and SARS-CoV-2 is possible to invade the CNS and cause severe neurological manifestation. Although the exact mechanism of this phenomenon is still unknown, viral neurotropism as seen in SARS-CoV may be responsible. The physicians should be alert when managing patients displaying encephalitic symptoms if the patients possess high-risk factors of SARS-CoV-2 infection. It is also essential to check the *M. Tuberculosis* infection status in SARS-CoV-2 infected patients as it may increase the symptom severity.

FUNDING

This report doesn't receive any specific grant from government or any private sectors.

ETHICAL CONSIDERATION

Patient had received signed written informed consent regarding publication of their medical data in journal article.

ACKNOWLEDGMENTS

All authors contributed equally in the writing of this report.

CONFLICT OF INTEREST

The author reports no conflicts of interest in this work.

AUTHOR CONTRIBUTION

All authors had contributed equally on manuscript preparation and agreed to final version of the manuscript for publication.

REFERENCES

- Li Q, et al. Early transmission dynamics in Wuhan, China, of novel coronavirus-infected pneumonia. *N Engl J Med*. 2020;382:1199–1207.
- Moriguchi T, et al. A first case of meningitis/encephalitis associated with SARS-Coronavirus-2. *Int J Infect Dis*. 2020;94:55–58 (2020).
- Xia H, Lazartigues E. Angiotensin-converting enzyme 2 in the brain: Properties and future directions. *J Neurochem*. 2008;107:1482–1494.
- Jia HP, et al. ACE2 Receptor Expression and Severe Acute Respiratory Syndrome Coronavirus Infection Depend on Differentiation of Human Airway Epithelia. *J Virol*. 2005;79:14614–14621.
- Kai H, Kai M. Interactions of coronaviruses with ACE2, angiotensin II, and RAS inhibitors-lessons from available evidence and insights into COVID-19. *Hypertens Res*. 2020;43(7):648–654. doi: [10.1038/s41440-020-0455-8](https://doi.org/10.1038/s41440-020-0455-8).
- Steardo L, Steardo L Jr, Zorec R, Verkhatsky A. Neuroinfection may contribute to pathophysiology and clinical manifestations of COVID-19. *Acta Physiol (Oxf)*. 2020;229(3):e13473. doi: [10.1111/apha.13473](https://doi.org/10.1111/apha.13473).
- Jebri N. Viral Encephalitis Associated with COVID-19: A Review of the Literature and Two Cases. *SSRN Electron J*. 2020;12:1–6. doi: [10.2139/ssrn.3573520](https://doi.org/10.2139/ssrn.3573520)
- Wu Y, Xu X, Chen Z, Duan J, Hashimoto K, Yang L, Liu C, Yang C. Nervous system involvement after infection with COVID-19 and other coronaviruses. *Brain Behav Immun*. 2020;87:18–22. doi: [10.1016/j.bbi.2020.03.031](https://doi.org/10.1016/j.bbi.2020.03.031).
- Thwaites G, Fisher M, Hemingway C, Scott G, Solomon T, Innes J; British Infection Society. British Infection Society guidelines for the diagnosis and treatment of tuberculosis of the central nervous system in adults and children. *J Infect*. 2009;59(3):167–87. doi: [10.1016/j.jinf.2009.06.011](https://doi.org/10.1016/j.jinf.2009.06.011).
- Be NA, Kim KS, Bishai WR, Jain SK. Pathogenesis of central nervous system tuberculosis. *Curr Mol Med*. 2009;9(2):94–9. doi: [10.2174/156652409787581655](https://doi.org/10.2174/156652409787581655).
- Donovan J, Figaji A, Imran D, Phu NH, Rohlwin U, Thwaites GE. The neurocritical care of tuberculous meningitis. *Lancet Neurol*. 2019;18(8):771–783. doi: [10.1016/S1474-4422\(19\)30154-1](https://doi.org/10.1016/S1474-4422(19)30154-1).
- Chaidir L, Annisa J, Dian S, Parwati I, Alisjahbana A, Purnama F, van der Zanden A, Ganiem AR, van Crevel R. Microbiological diagnosis of adult tuberculous meningitis in a ten-year cohort in Indonesia. *Diagn Microbiol Infect Dis*. 2018;91(1):42–46. doi: [10.1016/j.diagmicrobio.2018.01.004](https://doi.org/10.1016/j.diagmicrobio.2018.01.004).
- Liu K, Pan M, Xiao Z, Xu X. Neurological manifestations of the coronavirus (SARS-CoV-2) pandemic 2019–2020. *J Neurol Neurosurg Psychiatry*. 2020;91(6):669–670. doi: [10.1136/jnnp-2020-323177](https://doi.org/10.1136/jnnp-2020-323177).
- Baig AM, Khaleeq A, Ali U, Syeda H. Evidence of the COVID-19 Virus Targeting the CNS: Tissue Distribution, Host-Virus Interaction, and Proposed Neurotropic Mechanisms. *ACS Chem Neurosci*. 2020;11(7):995–998. doi: [10.1021/acscchemneuro.0c00122](https://doi.org/10.1021/acscchemneuro.0c00122).
- Desforges M, Le Coupance A, Dubeau P, Bourgouin A, Lajoie L, Dubé M, Talbot PJ. Human Coronaviruses and Other Respiratory Viruses: Underestimated Opportunistic Pathogens of the Central Nervous System? *Viruses*. 2019;12(1):14. doi: [10.3390/v12010014](https://doi.org/10.3390/v12010014).
- Koyuncu OO, Hogue IB, Enquist LW. Virus infections in the nervous system. *Cell Host Microbe*. 2013;13(4):379–93. doi: [10.1016/j.chom.2013.03.010](https://doi.org/10.1016/j.chom.2013.03.010).
- Lešková V, Jacková A, Vlasáková M, Vilček S. Genetic characterization of a border disease virus isolate originating from Slovakia. *Acta Virol*. 2013;57(1):17–25. doi: [10.4149/av_2013_01_17](https://doi.org/10.4149/av_2013_01_17).
- Fu Y, Cheng Y, Wu Y. Understanding SARS-CoV-2-Mediated Inflammatory Responses: From Mechanisms to Potential Therapeutic Tools. *Virol Sin*. 2020;35(3):266–271. doi: [10.1007/s12250-020-00207-4](https://doi.org/10.1007/s12250-020-00207-4).
- Mehta P, McAuley DF, Brown M, Sanchez E, Tattersall RS, Manson JJ; HLH Across Speciality Collaboration, UK. COVID-19: consider cytokine storm syndromes and immunosuppression. *Lancet*. 2020;395(10229):1033–1034. doi: [10.1016/S0140-6736\(20\)30628-0](https://doi.org/10.1016/S0140-6736(20)30628-0).
- Lau K, Yu W, Chu C, Lau S, Sheng B. Infection by SARS Coronavirus. *Emerg Infect Dis*. 2004;10: 2–4.
- Zaim S, Chong JH, Sankaranarayanan V, Harky A. COVID-19 and Multiorgan Response. *Curr Probl Cardiol*. 2020;45(8):100618. doi: [10.1016/j.cpcardiol.2020.100618](https://doi.org/10.1016/j.cpcardiol.2020.100618).
- McCray PB, et al. Lethal Infection of K18-hACE2 Mice Infected with Severe Acute Respiratory Syndrome Coronavirus. *J Virol*. 2007;81:813–821.
- Hayashi M, Sahashi Y, Baba Y, Okura H, Shimohata T. COVID-19-associated mild encephalitis/encephalopathy with a reversible splenic lesion. *J Neurol Sci*. 2020;415:116941. doi: [10.1016/j.jns.2020.116941](https://doi.org/10.1016/j.jns.2020.116941).
- Tadolini M, Codecasa LR, García-García JM, Blanc FX, Borisov S, Alfenaar JW, et al. Active tuberculosis, sequelae and COVID-19 co-infection: first cohort of 49 cases. *Eur Respir J*. 2020;56(1):2001398. doi: [10.1183/13993003.01398-2020](https://doi.org/10.1183/13993003.01398-2020).
- Chen Y, et al. Active or latent tuberculosis increases susceptibility to COVID-19 and disease severity. *Cold Spring Harb Lab*. 2020. doi: [10.1016/j.solener.2019.02.027](https://doi.org/10.1016/j.solener.2019.02.027).



This work is licensed under a Creative Commons Attribution